COLORECTAL

By Michel Hoessly, MD *Division of Medical Oncology & Hematology, Paoli Hospital*



Under care in our practice is a patient whose case is a good example of how PET scanning can mean earlier cancer diagnosis and treatment and, therefore, better prognosis. I initially treated this 43-year-old man in 1999, when he noticed blood in his stool, had undergone a colonoscopy, and been diagnosed with colorectal cancer. Our team at Paoli performed surgery on him, removing a portion of his colon, and we administered adjuvant chemotherapy.

The patient had no evidence of residual cancer in the subsequent years in which I followed him. In September 2003, though, his blood CEA blood began to rise. The antigen was above the normal range by November, at which point I referred him for an ultrasound, as well as CT and MRI scans. We imaged the liver, lung, abdomen, and other areas, but could identify no sites suspicious for metastasis (*See Fig. 1*).

Based on my concern about the now high CEA levels, though, I scheduled the patient for a PET scan. The imaging study revealed a lesion on the liver that gave every indication of being cancerous.

I sent the patient for surgery, and the team confirmed, and resected, an area of the left lobe of the liver that had a single area of colorectal cancer. The patient will soon complete his adjuvant chemotherapy.

Of interest here is that only PET scan showed the abnormal area (*See Fig. 2*). We feel that by taking advantage of this imaging modality, we can find and treat metastatic cancer earlier than we would otherwise. Without PET, we would probably have repeated the other imaging three months later. At that point, the patient's metastatic lesion would likely have been larger, and it is possible that the cancer might have spread to other locations.

CT

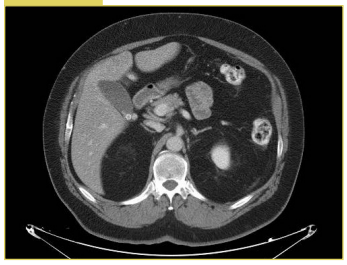

Fig. 1: *Normal CT of abdomen with contrast. Even in retrospect, no abnormality could be found in liver.*

PET

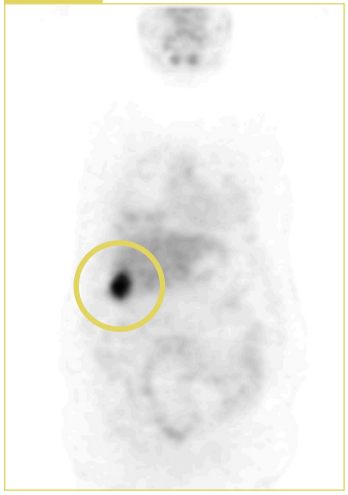

Fig. 2: *Whole-body PET scan. "Hot spot" along inferior edge of liver representing tumor.*

image review

By Harris P. Miller, MD *Main Line Health Imaging, Department of Radiology, Paoli Hospital*

Procedure: PET Imaging

We administered the positron emitting glucose tracer FDG-18 intravenously to the patient. PET imaging from the skull base through the pelvis was performed in a table scan time of 35 minutes.

The scan revealed a solitary area of rather intense, abnormal uptake that appears to be on the inferior edge of the liver near the junction of the right and left lobes. I cannot clearly identify a lesion in this area on the recent CT scan dated 11/19/2003. The exam was otherwise unremarkable.

In summary, there is an area of abnormal uptake in the inferior edge of the liver suspicious for the metastasis.

(Study performed at Lankenau Outpatient Imaging Center and read by radiologist at Paoli Hospital.)

for more information

610-645-2PET (2738)

www.mainlinehealth.org

Main Line Health Imaging

Bryn Mawr Hospital
Lankenau Hospital
Paoli Hospital

Membership on the medical staff of Main Line Hospitals does not constitute an employment or agency relationship.

MLHI.08/04.DL